

See discussions, stats, and author profiles for this publication at: <https://www.researchgate.net/publication/264867924>

Diagnosis of Takotsubo Cardiomyopathy – Mayo Clinic Criteria

Article *in* Circulation Journal · August 2014

DOI: 10.1253/circj.CJ-14-0859 · Source: PubMed

CITATIONS

38

READS

818

2 authors, including:



[Dawn C Scantlebury](#)

Queen Elizabeth Hospital, Barbados

25 PUBLICATIONS 193 CITATIONS

[SEE PROFILE](#)

All content following this page was uploaded by [Dawn C Scantlebury](#) on 05 September 2014.

The user has requested enhancement of the downloaded file. All in-text references [underlined in blue](#) are added to the original document and are linked to publications on ResearchGate, letting you access and read them immediately.



Diagnosis of Takotsubo Cardiomyopathy

– Mayo Clinic Criteria –

Dawn C Scantlebury, MD; Abhiram Prasad, MD

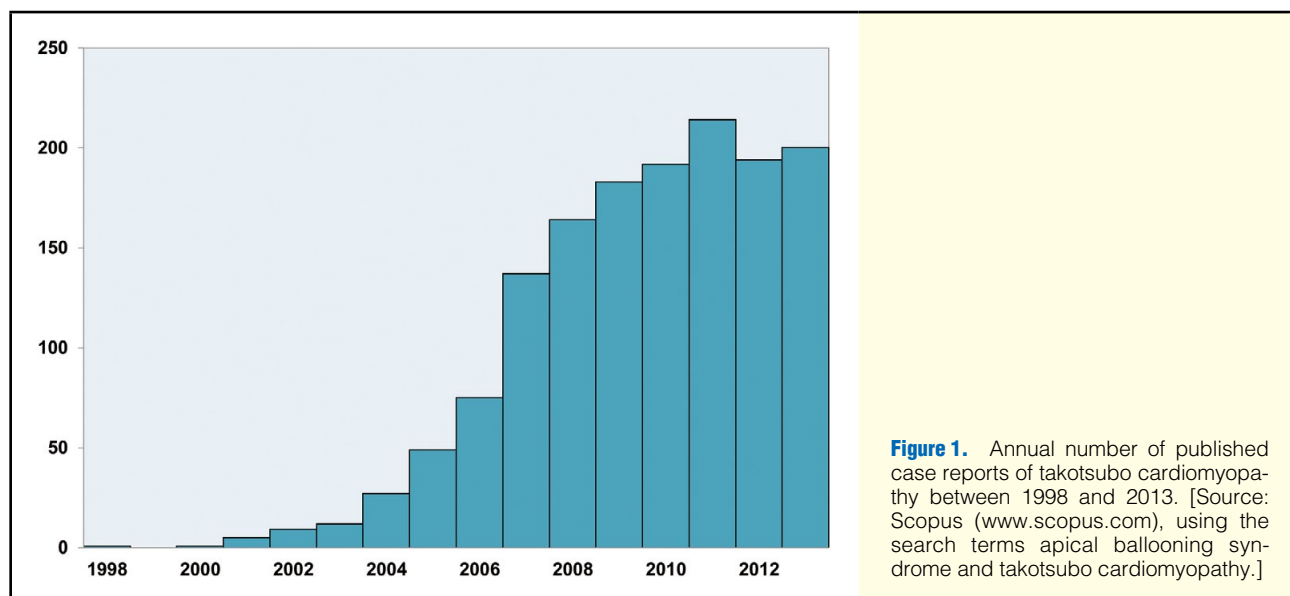
Takotsubo cardiomyopathy, also known as left ventricular apical ballooning syndrome and stress-induced cardiomyopathy, is typically characterized by transient systolic dysfunction of the apical and mid-segments of the left ventricle, in the absence of obstructive coronary artery lesions. Patients may present with symptoms and signs of acute coronary syndrome, and the provider is challenged to differentiate between these conditions. In this review, we guide the reader through the diagnostic pathway, focusing on differential diagnoses and diagnostic criteria for takotsubo cardiomyopathy. (*Circ J* 2014; **78**: 2129–2139)

Key Words: Apical ballooning syndrome; Diagnostic criteria; Myocardial infarction; Myocarditis; Takotsubo cardiomyopathy

In 1983, Dote et al noted an unusual systolic left ventricular (LV) configuration in a patient presenting to a Japanese hospital with an initial diagnosis of acute myocardial infarction (MI).¹ They coined the term “tako-tsubo-like” cardiomyopathy after noticing the resemblance of the ventricle to a Japanese octopus trapping pot (a takotsubo), which has a round bottom and narrow neck.² Following this report, multiple similar cases in the Japanese population were described. The initial

supposition was that the underlying cause of the cardiomyopathy was multivessel epicardial spasm that resulted in myocardial stunning.³ Tsuchihashi et al published the first large case series, from a Japanese multicenter study, reporting detailed characteristics and time course. They coined the alternative terminology of ‘left ventricular apical ballooning syndrome’.⁴

The disease was initially thought to be limited to the Japanese population but following the description by Tsuchihashi et al,



Received July 31, 2014; accepted August 1, 2014; released online August 13, 2014

Division of Cardiovascular Diseases, Department of Internal Medicine, Mayo Clinic, Rochester, MN, USA (D.C.S., A.P.); Cardiac Research Centre, St. George's, University of London, London, UK (A.P.)

Mailing address: Abhiram Prasad, MD, FRCP, FACC, FESC, Professor of Interventional Cardiology, St. George's, University of London, Cranmer Terrace, London SW17 0RE, UK. E-mail: aprasad@sgul.ac.uk

ISSN-1346-9843 doi:10.1253/circj.CJ-14-0859

All rights are reserved to the Japanese Circulation Society. For permissions, please e-mail: cj@j-circ.or.jp

Table 1. Mayo Clinic Criteria for ABS/TTC²⁰

1. Transient hypokinesia, akinesia, or dyskinesia of the left ventricular mid-segments with or without apical involvement; the regional wall motion abnormalities extend beyond a single epicardial vascular distribution; a stressful trigger is often, but not always present.*
2. Absence of obstructive coronary disease or angiographic evidence of acute plaque rupture.†
3. New electrocardiographic abnormalities (either ST-segment elevation and/or T-wave inversion) or modest elevation in cardiac troponin.
4. Absence of: <ol style="list-style-type: none"> Pheochromocytoma Myocarditis

ABS, apical ballooning syndrome; TTC, takotsubo cardiomyopathy; ACS, acute coronary syndrome.

*There are rare exceptions to these criteria such as those patients in whom the regional wall motion abnormality is limited to a single coronary territory.

†It is possible that a patient with obstructive coronary atherosclerosis may also develop ABS. However, this is very rare in our experience and in the published literature, perhaps because such cases are misdiagnosed as ACS.

In both of the above circumstances, the diagnosis of ABS should be made with caution and a clear stressful precipitating trigger must be sought.

the cardiomyopathy began to be recognized in the rest of the world. Desmet et al reported a case series of 13 white patients from Belgium with presentations similar to that of the Japanese apical ballooning syndrome,⁵ and Bybee et al reported a series of 16 patients from the USA.⁶ A stress-induced cardiomyopathy with wall motion abnormalities similar to that of takotsubo cardiomyopathy (TTC) had also been previously reported in case reports and smaller case series in France,⁷ Canada⁸ and the USA^{9,10} and would clearly have been characterized as TTC today. Since then, TTC has been reported all over the world^{11–13} and in most races and ethnicities.^{14–16}

The diagnosis of TTC is becoming more common, likely because of heightened awareness. **Figure 1** shows the annual number of published case reports between 1998 and 2013, reflecting the rapid rise in the recognition of the entity. TTC was incorporated into the American Heart Association (AHA) classification of cardiomyopathies as a unique cardiomyopathy in 2006¹⁷ and entered into National Center for Biotechnology Information (NCBI) databases as a distinct clinical entity in 2008. A study using the Nationwide Inpatient Sample discharge records for the year 2008 reported that TTC was diagnosed in 0.02% of all hospitalizations in the United States.¹⁸ It is the final diagnosis in approximately 2% of acute coronary syndrome (ACS) presentations.^{6,19,20}

There is no single universally accepted diagnostic definition of TTC. The National Library of Medicine's MeSH (medical subject headings) database defines TTC as "a transient left ventricular apical dysfunction or ballooning accompanied by electrocardiographic (ECG) T-wave inversions. This abnormality is associated with high levels of catecholamines, either administered or endogenously secreted from a tumor or during extreme stress". This description is insufficient to guide diagnosis, however, and implies causality to the extent that TTC and pheochromocytoma-mediated cardiomyopathy may be considered one and the same condition. The Mayo Clinic diagnostic criteria²⁰ (**Table 1**) were originally proposed in 2004²¹ and subsequently modified in 2008,²⁰ and are the most widely used in clinical practice and research. The criteria are based on expert consensus opinion, and are derived from the typical diagnostic pathway, described next, used to diagnose TTC and distinguish it from the major differential diagnoses.

Clinical Presentation

Typical Clinical Scenario

A 56-year-old woman with hypertension and type 2 diabetes mellitus presents to the emergency department with a history

of severe chest pain and dyspnea lasting 2–3 h. The chest pain started while she was rescuing her dog from a ravine after it was caught in a trap. On presentation, she is pain-free, but her ECG shows 1-mm ST-segment elevation in leads I and aVL. The troponin T level is 1.08 ng/ml, (normal <0.01). While awaiting transfer to the cardiac catheterization laboratory, she becomes acutely dyspneic, requiring intubation for pulmonary edema. Coronary angiography reveals mild luminal irregularities, with no significant obstructive lesion. Left ventriculography shows ventricular dilatation, with severe dysfunction of the mid and apical segments and ejection fraction of 20%. An intra-aortic balloon pump is placed and she is managed with aggressive supportive care. Her hemodynamics improve after 24 h and she can be weaned from the ventilator and inotropic agents. Plasma metanephrines and a non-contrast CT head are normal. Three days later, her echocardiogram reveals full recovery of LV function, with ejection fraction of 60%. The final diagnosis is TTC.

Demographics

TTC has a striking female predominance, with women accounting for 80–100% of cases in various reports.^{4,21–23} Women are typically postmenopausal, with mean age in different series of 62–76 years,^{21,24} although it has also been observed in women under the age of 50 (5–11% of cases),^{22,25} and premenopausal women.^{8,26,27} Because of their advanced age, affected patients with TTC often have cardiovascular comorbidities such as hypertension, dyslipidemia and smoking,¹⁸ making the clinical profile similar to patients with coronary artery disease (CAD) and ACS. Several studies have also reported a higher frequency of comorbid psychiatric disorders such as anxiety, depression and substance abuse.^{28–30} However, these are not universally present and hence not useful in making the diagnosis.

Stressors

A characteristic feature of the syndrome is its association with an identifiable stressful event, ranging from what may be considered an emotionally stressful event without a physical component to a physical stressor.^{31,32} Emotional stressors range from a discrete event such as receipt of bad news or exposure to a stressful event, among many others, to ongoing stressful situations, such as moving to a new residence, involvement in legal proceedings or ongoing dissatisfaction with relationships at home or at work. Physical stressors typically involve major surgery, orthopedic trauma, exacerbation of obstructive airways disease, and diagnostic/therapeutic cardiac³³ and non-cardiac procedures,³⁴ infections,²² and neurologic catastrophes³⁵ to name

Table 2. Studies Evaluating Electrocardiographic Criteria to Distinguish Between TTC and AMI*

Study, year of publication	TTC	AMI
Ogura et al (2003) ⁴⁶	TTC patients diagnosed by: 1. Suspected AMI by symptoms and ECG 2. Apical ballooning on LVgram, confirmed as transient on echo 2–3 weeks later 3. <50% luminal narrowing in coronary arteries n=13	Consecutive patients with typical clinical and ECG findings of AMI and confirmed lesion on angiography. Exclusions: idiopathic cardiomyopathy or prior MI n=13
Bybee et al (2007) ⁴⁵	Consecutive patients (20 identified, all women) with TTC by Mayo Clinic criteria; 2 with LBBB precluding ST analysis excluded n=18	2 AMI controls per TTC subject matched on age, gender Confirmed complete or subtotal LAD occlusion n=36
Jim et al (2009) ⁴⁷	TTC patients diagnosed by Mayo Clinic criteria January 2004–June 2006 Unclear whether consecutive n=8	Sex- and age-matched AMI subjects in same study period Documented LAD occlusion. No BBB, no AF n=27
Kosuge et al (2010) ⁴⁸	Diagnosis by Mayo Clinic criteria Patients with BBB, LVH, AF excluded n=33	AMI patients with documented LAD obstruction, severe stenosis, or thrombus No LVH, BBB or AF n=342
Kosuge et al (2012) ⁵¹ [subacute changes on ECG]	Consecutive TTC patients diagnosed by Mayo Clinic criteria; prompt normalization of systolic function Exclusions (both groups) BBB, LVH, AF, electrolyte abnormalities, metabolic disease, drugs that may affect ST analysis n=33	Consecutive AMI patients admitted within 6 h of symptom onset Documented LAD obstruction, severe stenosis or intracoronary thrombus No abnormal Q waves in leads V ₂₋₃ on discharge n=237

Study, year of publication	Predictors of TTC	Sensitivity	Specificity	Accuracy
Ogura et al (2003) ⁴⁶	1. Absence of reciprocal changes	100	69	84
	2. No abnormal Q waves present	83	69	76
	3. $\sum \text{STe } V_{4-6} / \sum \text{STe } V_{1-3} \geq 1^\dagger$	80	77	76
	4. Combination of 1 and 3	100	–	91
Bybee et al (2007) ⁴⁵	1. $\text{STe } V_2 < 1.75 \text{ mm plus } \text{STe } V_3 < 2.5 \text{ mm}^\ddagger$	67	94	–
	2. $[(3 \times \text{STe } V_2) + (\text{STe } V_3) + (2 \times \text{STe } V_3)] < 11.5 \text{ mm}^\ddagger$	94	72	–
Jim et al (2009) ⁴⁷	$\text{STe } II \geq 1.0 \text{ mm}^\ddagger$	62.5	92.6	85.7
	$\text{STe } \geq 1.0 \text{ mm in } \geq 2 \text{ inferior leads}^\ddagger$	50.0	92.6	82.8
	$\sum \text{STe } V_{4-6} \geq \sum \text{STe } V_{1-3}$	50.0	70.4	65.7
Kosuge et al (2010) ⁴⁸	1. No abnormal Q waves	42	74	71
	2. No reciprocal changes	94	49	53
	3. STe-aVR (ie, ST depression $>0.5 \text{ mm}$ in aVR)	97	75	77
	4. No $\text{STe } V_1$ ($\text{STe } V_1 < 1.0 \text{ mm}$)	94	71	73
	5. Combination of 3 and 4 [†]	91	96	95
Kosuge et al (2012) ⁵¹ [subacute changes on ECG]	1. Positive T waves in aVR	100	87	89
	2. No negative T waves in V ₁	94	68	72
	3. Combination of 1 and 2	94	95	94

*Please note small sample size of TTC patients in all studies.

AF, atrial fibrillation; AMI, anterior myocardial infarction; BBB, bundle branch block; Σ , sum; Echo, echocardiogram; ECG, electrocardiogram; LAD, left anterior descending artery; LVgram, left ventriculogram; LVH, left ventricular hypertrophy; MI, myocardial infarction; STe, ST-segment elevation; TTC, takotsubo cardiomyopathy.

[†]Johnson et al compared 33 TTC patients to 263 AMI patients in order to validate these 6 criteria.⁵⁰ The criteria showed a marked reduction in diagnostic accuracy in their cohort except for $\text{STe } V_2 < 1.75 \text{ mm plus } \text{STe } V_3 < 2.5 \text{ mm}$ (79% sensitivity and 73% specificity).

a few. Indeed, the condition closely resembles the entity previously known as neurologic stunned myocardium, which is now commonly considered to be a manifestation of TTC.³⁶ Many case series have included exhaustive lists of specific stressful

situations associated with the development of the cardiomyopathy.^{37,38} The only conclusion that can be gained from reviewing these lists is that virtually *any* event or situation, however minor, may potentially be the precipitant for TTC. It is also

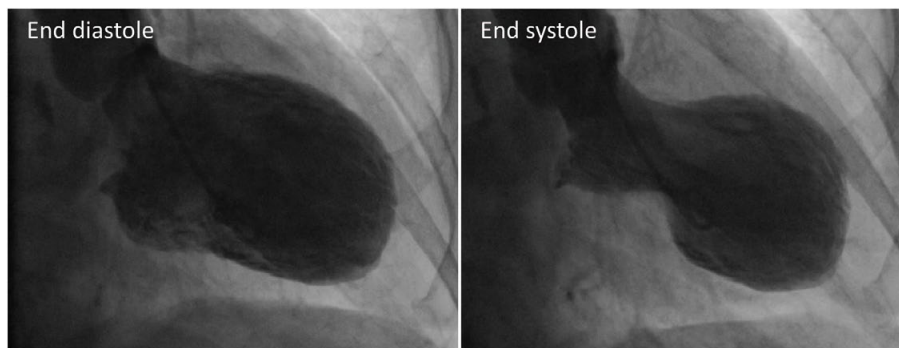


Figure 2. Left ventriculogram demonstrating the classic pattern of takotsubo cardiomyopathy: akinesis of the left ventricular apex, with preserved function at the base.

worth noting that a stressor is not identified in up to one-third of individuals.³⁷

MI may also be precipitated by specific stressors. The 2004 earthquakes in Niigata, Japan, were associated with an increase in both MI and TTC.³⁹ Similar findings have been reported in other regions of the world.⁴⁰ Thus, association with a stressful event might suggest the diagnosis of TTC but is not sufficient to differentiate from ACS.

Symptoms and Signs

Chest pain and dyspnea are the most common presenting symptoms.^{4,21} The chest pain often has the characteristics of angina. Cardiac arrest,⁴¹ syncope and arrhythmias⁴² have also been described. In patients who are already critically ill with other medical conditions, a clue to the diagnosis may be clinical worsening, or may be incidentally discovered after noting ECG changes or biomarker elevations.⁴¹ The symptoms and signs are similar to those seen in other acute cardiac conditions characterized by acute myocardial ischemia or heart failure, such as ACS and myocarditis, and hence do not help in the differential diagnoses.

Investigations

ECG Findings

The ECG features of TTC are not diagnostic, but are often characterized by evolutionary changes:

Initial Presentation The ECG findings at initial presentation are often those associated with myocardial ischemia or an injury pattern. The first description of TTC by Tsuchihashi et al reported ST-segment elevation in 79 of 88 (90%) patients, with reciprocal ST-segment changes in 32 patients, 1 patient with ST depression without ST elevation and 8 patients had T-wave inversion without ST-segment deviation.⁴ However, this was a highly selected group because the patients were drawn from a Japanese MI registry. With greater recognition of the condition and with patients being diagnosed outside of a characteristic MI presentation, the spectrum of ECG patterns has broadened.

A case series from Mayo Clinic divided 105 retrospectively identified patients meeting the criteria for TTC into 3 groups according to the ECG at presentation.⁴³ One group had ST-segment elevation >1 mm in 2 contiguous leads or new left bundle branch block (ie, typical ST-segment elevation MI

(STEMI) criteria); the second group had T-wave inversion >3 mm in 3 contiguous leads without significant ST shifts; and the third group had nonspecific ST-segment changes or a normal ECG. Each group comprised approximately one-third of the overall cohort, with no discernable difference in clinical presentation or outcomes in the groups.

Another series from the Minneapolis Heart Institute evaluated 59 consecutive patients with TTC.⁴⁴ ST-segment elevation was present in 56% of patients, predominantly in the precordial leads; 17% had widespread T-wave inversion, 10% had healed anterior MI (abnormal Q waves or abnormal R wave progression in 2 or more contiguous anterior leads); 17% had either normal ECG or nonspecific changes. When compared with patients presenting with MI because of left anterior descending (LAD) coronary artery occlusion, they found that the mean amplitude of ST-segment elevation was lower in the TTC group than in the LAD occlusion group (1.4 vs. 2.4 mm), but there was significant overlap. There was no significant difference in the presence of abnormal anterior Q waves or 12-lead QRS amplitude between the groups.

Other investigators have conducted similar studies evaluating the ECG differences between TTC and acute anterior MI on presentation.^{45–48} Kosuge et al retrospectively evaluated 33 TTC patients and 342 patients with a first anterior MI.⁴⁸ They reported that the combination of the presence of ST depression in lead aVR and the absence of ST-segment elevation in lead V₁ identified TTC with 91% sensitivity, 96% specificity, and 95% predictive accuracy. In addition to the small sample size of TTC patients, there are several limitations of the study. The high frequency of ST-segment elevation in the limb leads challenges the assumption that the comparison group should be isolated anterior ST elevation; and the pattern described (ST depression in aVR with no ST elevation in V₁) may occur in a distal occlusion with a wrap-around LAD.⁴⁹ Criteria used in other studies to differentiate TTC from anterior MI in patients presenting with anterior ST elevation include absence of reciprocal changes, absence of abnormal Q waves and ratio of ST elevation in leads V_{4–6} to V_{1–3} ≥1⁴⁶ and absence of ST depression or concurrent inferior ST elevation. **Table 2** summarizes these studies. The criteria all have less than perfect diagnostic accuracy and given the consequences of a missed diagnosis, do not allow for reliable differentiation between the 2 conditions in the emergency setting to guide management (eg, decision to undergo emergency coronary angiography).⁵⁰

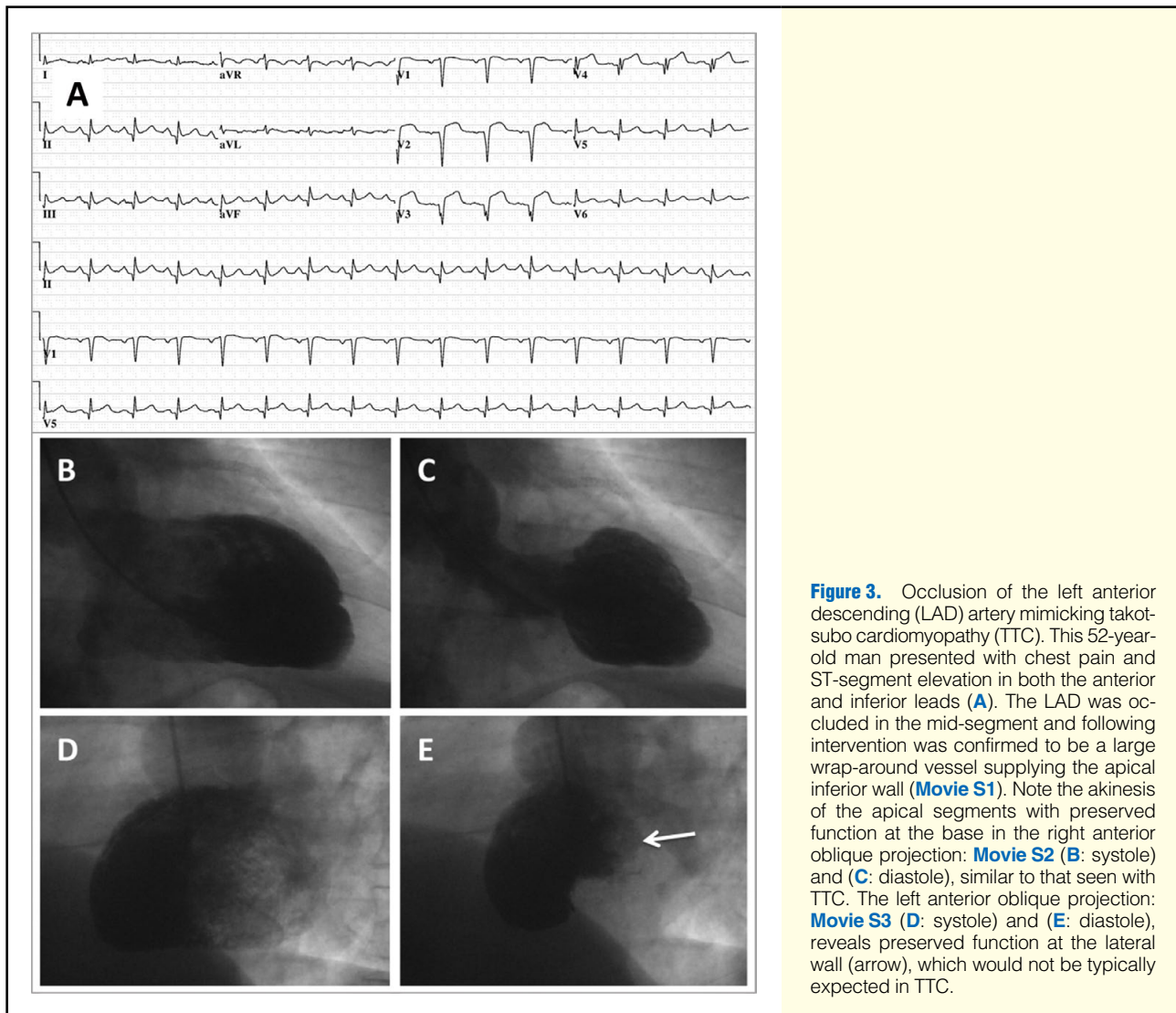


Figure 3. Occlusion of the left anterior descending (LAD) artery mimicking takotsubo cardiomyopathy (TTC). This 52-year-old man presented with chest pain and ST-segment elevation in both the anterior and inferior leads (A). The LAD was occluded in the mid-segment and following intervention was confirmed to be a large wrap-around vessel supplying the apical inferior wall (Movie S1). Note the akinesis of the apical segments with preserved function at the base in the right anterior oblique projection: Movie S2 (B: systole) and (C: diastole), similar to that seen with TTC. The left anterior oblique projection: Movie S3 (D: systole) and (E: diastole), reveals preserved function at the lateral wall (arrow), which would not be typically expected in TTC.

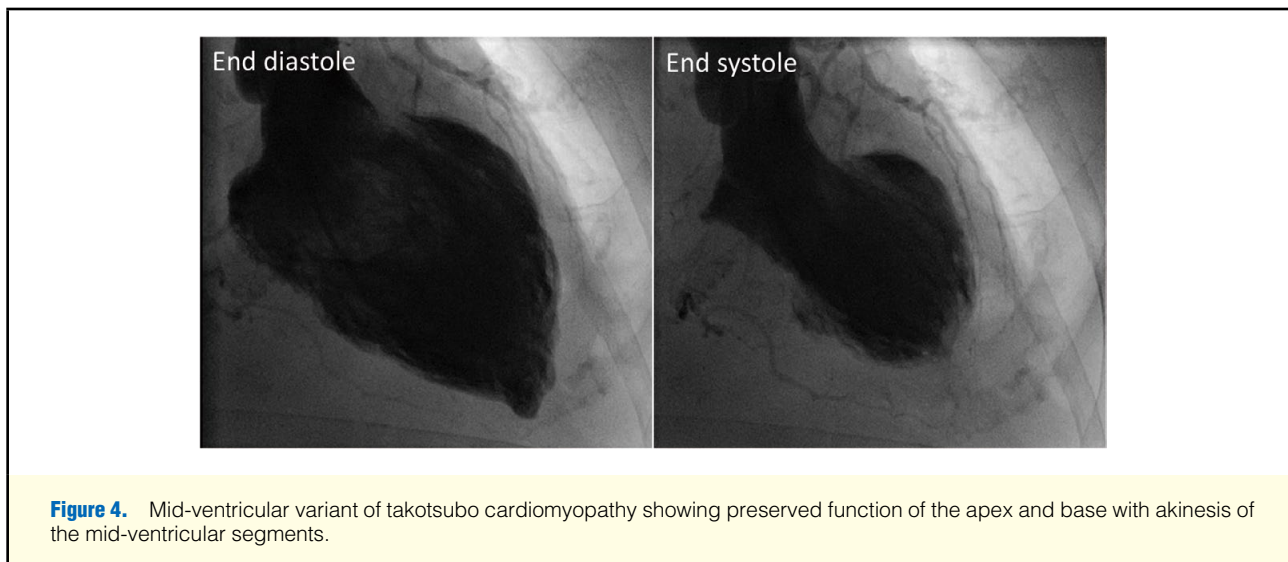


Figure 4. Mid-ventricular variant of takotsubo cardiomyopathy showing preserved function of the apex and base with akinesis of the mid-ventricular segments.

Table 3. Proposed Diagnostic Criteria for TTC

Diagnostic criteria	Initial Mayo Clinic (2004) ²¹	Revised Mayo Clinic (2008) ²⁰	Japanese (2007) ⁷⁵
Morphology			
Left ventricular wall motion abnormalities...	m	m	x
...extending beyond a single epicardial vascular distribution	m	m	x
Involvement of apical and mid-ventricular segments (classic apical ballooning pattern)	m	o	m
Mid-ventricular segments (with or without apical involvement)	x	o	x
Inclusion of right ventricular wall motion abnormalities	x	x	o
Dynamic outflow tract obstruction	x	x	o
Time course			
'Transient'	m	m	x
(Near) Complete recovery within days to weeks	x	x	m
Evidence of ischemia/myonecrosis			
New and dynamic ST-segment deviation, T-wave inversion or left BBB	m	o	x
Typical evolution of ECG changes (see text) including QT prolongation	x	x	o
'Mild' or 'modest' increase in cardiac biomarkers	x	o	o
Exclusions			
Potential coronary culprit (eg, stenosis, evidence of plaque rupture, dissection, thrombosis or spasm)	m	m	m
Myocarditis	m	m	m
Pheochromocytoma	m	m	m
Cerebrovascular disease	m	x	m
Hypertrophic cardiomyopathy	m	x	x
Other pathological conditions that may explain regional dysfunction	x	x	m
Other features			
Symptoms similar to that of ACS	x	x	o
Elderly patient	x	x	o
Postmenopausal woman	x	x	o
Antecedent stressful event	x	o	o
Comorbidity with variety of illnesses	x	x	x
Normal or near normal filling pressures	x	x	x
Abnormal myocardial scintigraphy	x	x	o

m, mandatory; o, optional; x, no mention or not explicitly stated. Other abbreviations as in Tables 1,2.

*The John's Hopkins criteria did not specify left ventricle for the first criterion.

(Table 3 continued the next page.)

Subacute Phase Beyond the acute setting, the evolution of the ECG is often stereotypical. Following resolution of ST-segment elevation, diffuse and often deep T-wave inversion develops.⁵¹ Q waves are uncommon⁴ and usually transient.⁵² QT prolongation is almost universally reported.^{52,53} A study by Mitsuma et al⁵⁴ aimed to clarify the phases of the ECG in 9 women with TTC. They suggested 4 phases: initial ST elevation, followed by transient T-wave inversion (days 1–3) then T-wave recovery in some patients (days 2–6) followed by giant T-wave inversion associated with prominent QT prolongation, which persisted for up to at least 2 months. This evolution of findings may seem to be of some benefit in differentiating MI from TTC, but any of these ECG patterns may be seen in myocardial ischemia caused by CAD. The deep T-wave inversions associated with QT prolongation, often described as the typical ECG of TTC,⁵⁵ is also reminiscent of the Wellen's ECG pattern,⁵⁶ classically thought to be caused by a critical stenosis of the proximal LAD.⁵⁷

Biomarkers

Consistent with the ECG findings, TTC is associated with elevation in cardiac biomarkers of myonecrosis. The initial de-

scription by Tsuchihashi reported creatinine kinase elevation in 56% of the patients. Subsequent studies using cardiac troponin report almost universal elevations, because of the greater sensitivity of the biomarker,^{5,21,44} especially with contemporary assays. The pattern of troponin elevation differs considerably from acute STEMI. Peak troponin T levels are modest, mean ~60-fold the upper limit of normal (ULN, defined as 99th percentile) as opposed to >400-fold the ULN for acute STEMI,^{44,58} similar to those seen in non-ST-segment elevation MI.^{47,59} Nascimento et al used this finding of modest elevation of troponin in patients with TTC to devise a criterion for differentiating between STEMI and TTC.⁶⁰ They derived the troponin-ejection fraction product (TEFP) by obtaining the product of the peak troponin I level and the echocardiographically obtained ejection fraction. A TEFP ≥ 250 had a sensitivity of 95%, specificity of 87% and overall accuracy of 91% to identify STEMI.

Plasma B-type natriuretic peptide (BNP) levels are usually higher in TTC than in STEMI, and the ratio of BNP to peak troponin levels may differentiate TTC from STEMI.^{58,59} The levels of BNP (as well as NT-pro BNP) may correlate with the extent of myocardial dysfunction,⁶¹ but not hemodynamic pa-

Diagnostic criteria	Johns Hopkins (2012) ⁸³	Gothenburg (2013) ⁸⁴	Takotsubo Italian Network (2014) ⁸⁰	Madias (2014) ⁸¹
Morphology				
Left ventricular wall motion abnormalities...	m*	m	m	o
...extending beyond a single epicardial vascular distribution	m	x	m	x
Involvement of apical and mid-ventricular segments (classic apical ballooning pattern)	x	x	x	x
Mid-ventricular segments (with or without apical involvement)	x	x	x	x
Inclusion of right ventricular wall motion abnormalities	x	x	x	o
Dynamic outflow tract obstruction	x	x	x	x
Time course				
'Transient'	x	m	m	m
(Near) Complete recovery within days to weeks	m	x	m	x
Evidence of ischemia/myonecrosis				
New and dynamic ST-segment deviation, T-wave inversion or left BBB	o	x	m	o
Typical evolution of ECG changes (see text) including QT prolongation	o	x	x	o
'Mild' or 'modest' increase in cardiac biomarkers	o	m	m	x
Exclusions				
Potential coronary culprit (eg, stenosis, evidence of plaque rupture, dissection, thrombosis or spasm)	m	m	m	m
Myocarditis	x	m	m	m
Pheochromocytoma	x	m	x	m
Cerebrovascular disease	x	x	x	x
Hypertrophic cardiomyopathy	x	x	x	x
Other pathological conditions that may explain regional dysfunction	x	m	x	m
Other features				
Symptoms similar to that of ACS	x	x	x	x
Elderly patient	x	x	x	x
Postmenopausal woman	x	x	o	o
Antecedent stressful event	o	o	o	o
Comorbidity with variety of illnesses	x	x	x	o
Normal or near normal filling pressures	x	m	x	x
Abnormal myocardial scintigraphy	x	x	x	x

rameters⁵⁹ and can remain elevated for months following the acute event.⁶¹ These patterns of biomarker elevations are noteworthy, but there is no threshold identified that has clinically meaningful sensitivity or specificity for distinguishing acute MI from TTC.

Multiple case reports describe TTC following exogenous administration of catecholamines,^{62–64} and recent evidence suggests that the pathophysiology of TTC may lie in changes in β -adrenergic receptor signaling.⁶⁵ Despite this, the role of catecholamine levels in making the diagnosis of TTC is unclear. Wittstein et al demonstrated that on hospital day 1, patients with TTC had plasma levels of catecholamines (epinephrine, norepinephrine and dopamine) that were 2–3-fold that seen in patients with Killip class III acute heart failure after MI and 7–34-fold of normal.⁶⁶ The type of MI was not specified. A further study showed that catecholamine levels in TTC were higher with worsening Killip class.⁶⁷ This finding has not been universally reported, however. Madhavan et al did not demonstrate any difference in plasma levels of fractionated metanephrine and normetanephrine or 24-h levels of fractionated catecholamines and metanephrines between TTC and STEMI patients.⁵⁸

Imaging

The typical wall motion abnormalities of TTC are clearly demonstrated on left ventriculography. The classic pattern of hypokinesis, akinesis or dyskinesis of the apical and mid-ventricular segments, *extending beyond a single epicardial coronary distribution* (Figure 2), is perhaps one of the most helpful diagnostic features.²⁰ Though this is an important aspect of TTC, there are potential pitfalls. For example, transient or persistent proximal or mid-LAD occlusion of a large artery may produce a regional wall motion abnormality pattern that mimics apical ballooning (Figure 3). Thus, it is essential to carefully evaluate for regional wall motion abnormality in the distribution of all 3 major epicardial coronary artery distributions to distinguish the classic form of TTC from a large LAD territory infarct or stunning.⁶⁸ We have previously shown that the presence of lateral wall systolic dysfunction in the left anterior oblique projection of a left ventriculogram is a useful differentiating feature between TTS and anterior MI.⁶⁸ Other variant patterns of regional wall motion abnormalities of TTC have been described, and although less common, tend to be pathognomonic. These include the mid-ventricular variant in which apical function is preserved, (or perhaps recovered) (Figure 4) or inverted/reverse TTC, in which the mid- and apical segments are preserved

Table 4. Approach to Diagnosis of TTC		
	Findings	Caution
Key characteristics		
1. Wall motion abnormalities (generally extending beyond a typical coronary distribution)	Classic: apical and mid hypo-, a- or dyskinesis with or without right ventricular involvement Variants: mid-ventricular segments only (mid-ventricular variant); basal segments alone involved (reverse/inverted TTC)	These patterns may suggest TTC but should be accompanied by assessment of coronaries to rule out multivessel coronary disease Milder cases of TTC may occasionally appear to fit a coronary territory, especially if there is limited left ventricular imaging
2. Evidence of myocyte injury		
a. Biomarker elevation	Typically only modest elevation	Similar magnitude to that seen in non-ST-segment elevation MI
b. ECG changes	Frequent presentation: ST elevation Classic: deep symmetrical T-wave inversion in the anterior leads with QT prolongation	Should be managed as ST-segment elevation MI until proven otherwise, by excluding coronary occlusion with angiography This pattern may be seen with a high-grade proximal LAD lesion
Supportive clinical features		
Postmenopausal woman		Diagnosis made in only 2% of postmenopausal women presenting with ACS-type symptoms ACS must be first differential
Preceding stressor		Up to 1/3 of TTC cases in series do not have an identifying stressor ACS may be precipitated by similar stressors
Key exclusions		
Coronary obstruction sufficient to explain wall motion abnormalities		MI and TTC have been reported together in some case reports. The key to TTC diagnosis is the inability to explain the degree of wall motion changes based on the coronary anatomy
Myocarditis	CMR criteria may be of benefit in differentiating between myocarditis, TTC and MI	Aside from myocarditis, other conditions may present with a transient cardiomyopathy (eg, tachycardia-induced cardiomyopathy, peripartum cardiomyopathy in the appropriate setting, other endocrine abnormalities such as thyrotoxicosis) and should be considered
Pheochromocytoma	Cardiac findings indistinguishable from TTC. Should be considered so that the diagnosis of pheochromocytoma is not overlooked. Catecholamine levels should be measured in select cases where there is no clear explanation for TTC-like regional wall motion abnormality	

CMR, cardiac magnetic resonance imaging. Other abbreviations as in Tables 1,2.

with akinesis/hypokinesis of the basal regions.²⁰

Echocardiography and cardiac magnetic resonance imaging (CMR) also readily demonstrate the typical wall motion abnormalities. Echocardiography is frequently performed prior to coronary angiography and left ventriculography in patients who present without ST-segment elevation. It may also be performed in the case of ST-segment elevation, where the risk of coronary angiography and intervention outweighs the benefits, such as critically ill patients in the intensive care unit, or patients with prohibitively high bleeding risk. In these situations, the pattern of wall motion abnormalities may suggest the diagnosis of TTC. A retrospective echocardiography study also demonstrated that there is right ventricular involvement in 30% of TTC cases.⁶⁹

Repeat echocardiography is useful (and recommended) to demonstrate recovery of LV function. Echocardiography may also reveal LV outflow tract obstruction, which may occur because of the hyperdynamic basal function, and altered mitral valve motion.¹⁰ This might initially suggest a diagnosis of hypertrophic cardiomyopathy in patients with significant LV hypertrophy, but the accompanying regional wall motion abnormalities and the clinical presentation allows differentiation of hypertrophic cardiomyopathy.

Similar to the ECG, there is intense interest in the use of non-invasive imaging for differentiation between TTC and acute MI, and CMR shows some promise in this regard. Late gadolinium enhancement (LGE) on CMR usually represents fibrosis. In MI, the distribution of LGE is subendocardial or transmural,⁷⁰ indicating the extent of infarction. In non-ischemic cardiomyopathy, there may be an isolated mid-wall or subepicardial pattern of enhancement⁷¹ and myocarditis produces a patchy distribution of LGE,⁷² among other manifestations on CMR. There are conflicting data on the presence or absence of LGE in TTC. Some studies report no LGE, allowing early and accurate differentiation from MI,^{67,73} whereas others report LGE⁷⁴ in a minority of TTC cases,^{75,76} thus rendering presence or absence of LGE less useful for differentiation. The answer to the discrepancy may lie in the threshold used in various studies for defining LGE. A large prospective multicenter study in Europe and North America enrolled 256 consecutive patients with a prospective diagnosis of TTC (by Mayo Clinic criteria).⁷⁷ Focal or patchy LGE was identified in 22% of patients when a signal intensity threshold of 3 standard deviations (SD) above the mean of remote myocardium was used. When a threshold of 5 SD was used, no patients demonstrated LGE. The authors devised a set of 4 MRI-based criteria for the diagnosis of TTC

based on their findings: a typical pattern of LV dysfunction; myocardial edema; absence of significant necrosis/fibrosis; and markers for myocardial inflammation. A confirmatory criterion was the resolution of these criteria after ≥ 4 -week follow-up. Indeed, regardless of the imaging modality used, confirmation of complete recovery of ventricular function (as is the case in virtually all patients), usually several weeks to months after the acute episode is important in order to provide additional supportive evidence for the diagnosis of TTC.

Coronary Angiography

In the acute phase, a presentation with ST-segment elevation on the ECG and symptoms suggestive of myocardial ischemia mandate immediate evaluation with coronary angiography in order to exclude coronary occlusion. There is no provision in the guidelines for delay for a suspected diagnosis of TTC. Coronary angiography may be completely normal, but the presence of CAD does not preclude a diagnosis of TTC.^{19,78,79} Indeed, acute MI itself has been proposed as a stressor for the subsequent development of TTC.^{80,81} However, a diagnosis of TTC in the presence of significant coronary disease must be made cautiously, and requires careful integration of the clinical presentation, coronary anatomy and myocardial imaging.

When a patient presents less acutely (eg, with nonspecific ECG findings, or with biomarker elevation and typical imaging findings in the setting of an acute illness), there may be some reluctance to perform coronary imaging.⁸² This must be balanced against the implications of missing the diagnosis of multivessel CAD, by inaccurately diagnosing TTC. *Therefore, our recommendation is that the coronary anatomy be defined in patients suspected of TTC, using noninvasive angiography in cases when cardiac catheterization may not be deemed safe or feasible.*

Mayo Clinic Diagnostic Criteria

In the absence of a single diagnostic test, the Mayo Clinic diagnostic criteria (**Table 1**) seek to succinctly incorporate the key features described above that help to differentiate TTC from its main differentials, namely ACS, myocarditis, and pheochromocytoma. The criteria are designed to be practically applied at the time of admission. The need for follow-up imaging is implied in order to demonstrate that the ventricular dysfunction was transient. **Table 3** provides a summary of the other proposed diagnostic criteria and features that are and are not shared with the Mayo Clinic criteria.^{75,80,81,83,84} The underlying principle behind the single criterion that is shared by all of these diagnostic criteria (absence of a coronary lesion that could account for the wall motion abnormality) is that TTC is currently a diagnosis of exclusion.

Because our understanding of the pathophysiology of TTC is limited at this time, these criteria are likely to continue to change and evolve over time. In **Table 4**, we suggest a framework by which the diagnosis of TTC be approached, giving the expected findings for each criterion. This is not an attempt at developing another set of diagnostic criteria but presents a brief summary to facilitate understanding of the condition. Note that no one finding is adequate for the diagnosis as there are multiple provisos. Each part should therefore be satisfied in order to make a diagnosis. We currently have no specific therapies for TTC but failure to recognize and treat one of its differentials may be potentially catastrophic. The responsibility of the physician is to first do no harm. We encourage the reader to exercise due diligence in making the diagnosis of TTC.

Disclosures

None.

References

1. Aizawa K, Suzuki T. Takotsubo cardiomyopathy: Japanese perspective. *Heart Fail Clin* 2013; **9**: 243–247, x.
2. Sato H, Tateishi H, Dote K, Uchida T, Ishihara M. Tako-tsubo-like left ventricular dysfunction due to multivessel coronary spasm. *In: Kodama K, Haze K, Hori M, editors. Clinical aspect of myocardial injury: From ischemia to heart failure.* Tokyo: Kagakuhyoronsha Publishing Co, 1990; 56–64.
3. Dote K, Sato H, Tateishi H, Uchida T, Ishihara M. Myocardial stunning due to simultaneous multivessel coronary spasms: A review of 5 cases. *J Cardiol* 1991; **21**: 203–214 (in Japanese).
4. Tsuchihashi K, Ueshima K, Uchida T, Oh-mura N, Kimura K, Owa M, et al. Transient left ventricular apical ballooning without coronary artery stenosis: A novel heart syndrome mimicking acute myocardial infarction: Angina Pectoris-Myocardial Infarction Investigations in Japan. *J Am Coll Cardiol* 2001; **38**: 11–18.
5. Desmet WJ, Adriaenssens BF, Dens JA. Apical ballooning of the left ventricle: First series in white patients. *Heart* 2003; **89**: 1027–1031.
6. Bybee KA, Prasad A, Barsness GW, Lerman A, Jaffe AS, Murphy JG, et al. Clinical characteristics and thrombolysis in myocardial infarction frame counts in women with transient left ventricular apical ballooning syndrome. *Am J Cardiol* 2004; **94**: 343–346.
7. Pavin D, Le Breton H, Daubert C. Human stress cardiomyopathy mimicking acute myocardial syndrome. *Heart* 1997; **78**: 509–511.
8. Kovacs KA, Burggraf GW, Dewar CL. Reversible cardiogenic shock in an angry woman: Case report and review of the literature. *Can J Cardiol* 1996; **12**: 689–693.
9. Ryan TJ, Fallon JT. Case 18–1986. *N Engl J Med* 1986; **314**: 1240–1247.
10. Villareal RP, Achari A, Wilansky S, Wilson JM. Anteroapical stunning and left ventricular outflow tract obstruction. *Mayo Clinic Proc* 2001; **76**: 79–83.
11. Teh AW, New G, Cooke J. A single-centre report on the characteristics of Tako-tsubo syndrome. *Heart Lung Circ* 2010; **19**: 63–70.
12. Varela UC, Bohn RR, Varleta OP, Concepcion CR. Recurrence of stress cardiomyopathy after an earthquake: Report of one case. *Rev Med Chil* 2011; **139**: 79–83 (in Spanish).
13. Bellandi B, Salvadori C, Parodi G, Ebert AG, Petix N, Del Pace S, et al. Epidemiology of Tako-tsubo cardiomyopathy: The Tuscany Registry for Tako-tsubo Cardiomyopathy. *G Ital Cardiol (Rome)* 2012; **13**: 59–66 (in Italian).
14. Nascimento FO, Santana O, Perez-Caminero M, Benjo AM. The characteristics of stress cardiomyopathy in an ethnically heterogeneous population. *Clinics (Sao Paulo)* 2011; **66**: 1895–1899.
15. Tsui PT, Cheung KC, Lau CL, Choy CC. A Chinese patient with severe takotsubo cardiomyopathy. *Int J Cardiol* 2007; **119**: 134–135.
16. Pezzo SP, Hartlage G, Edwards CM. Takotsubo cardiomyopathy presenting with dyspnea. *J Hosp Med* 2009; **4**: 200–202.
17. Maron BJ, Towbin JA, Thiene G, Antevich C, Corrado D, Arnett D, et al. Contemporary definitions and classification of the cardiomyopathies: An American Heart Association Scientific Statement from the Council on Clinical Cardiology, Heart Failure and Transplantation Committee; Quality of Care and Outcomes Research and Functional Genomics and Translational Biology Interdisciplinary Working Groups; and Council on Epidemiology and Prevention. *Circulation* 2006; **113**: 1807–1816.
18. Deshmukh A, Kumar G, Pant S, Rihal C, Murugiah K, Mehta JL. Prevalence of Takotsubo cardiomyopathy in the United States. *Am Heart J* 2012; **164**: 66–71.e1, doi:10.1016/j.ahj.2012.03.020.
19. Prasad A, Dangas G, Srinivasan M, Yu J, Gersh BJ, Mehran R, et al. Incidence and angiographic characteristics of patients with apical ballooning syndrome (takotsubo/stress cardiomyopathy) in the HORIZONS-AMI trial: An Analysis from a Multicenter, International Study of ST-elevation Myocardial Infarction. *Catheter Cardiovasc Interv* 2014; **83**: 343–348.
20. Prasad A, Lerman A, Rihal CS. Apical ballooning syndrome (Tako-Tsubo or stress cardiomyopathy): A mimic of acute myocardial infarction. *Am Heart J* 2008; **155**: 408–417.
21. Bybee KA, Kara T, Prasad A, Lerman A, Barsness GW, Wright RS, et al. Systematic review: Transient left ventricular apical ballooning: A syndrome that mimics ST-segment elevation myocardial infarction. *Ann Intern Med* 2004; **141**: 858–865.
22. Brinjkji W, El-Sayed AM, Salka S. In-hospital mortality among patients with takotsubo cardiomyopathy: A study of the National Inpatient Sample 2008 to 2009. *Am Heart J* 2012; **164**: 215–221.

23. Leurent G, Larralde A, Boulmier D, Fougerou C, Langella B, Ollivier R, et al. Cardiac MRI studies of transient left ventricular apical ballooning syndrome (takotsubo cardiomyopathy): A systematic review. *Int J Cardiol* 2009; **135**: 146–149.
24. Pilgrim TM, Wyss TR. Takotsubo cardiomyopathy or transient left ventricular apical ballooning syndrome: A systematic review. *Int J Cardiol* 2008; **124**: 283–292.
25. Patel SM, Chokka RG, Prasad K, Prasad A. Distinctive clinical characteristics according to age and gender in apical ballooning syndrome (takotsubo/stress cardiomyopathy): An analysis focusing on men and young women. *J Card Fail* 2013; **19**: 306–310.
26. D'Amato N, Colonna P, Brindicci P, Campagna MG, Petrillo C, Cafarelli A, et al. Tako-Tsubo syndrome in a pregnant woman. *Eur J Echocardiogr* 2008; **9**: 700–703.
27. Ehl NF, Zurek M, Rickli H, Maeder MT. “Double takotsubo”: First description of the sequence of classical followed by inverted type in a young woman. *Int J Cardiol* 2014; **174**: e36–e37, doi:10.1016/j.ijcard.2014.04.064.
28. Summers MR, Lennon RJ, Prasad A. Pre-morbid psychiatric and cardiovascular diseases in apical ballooning syndrome (tako-tsubo/stress-induced cardiomyopathy): Potential pre-disposing factors? *J Am Coll Cardiol* 2010; **55**: 700–701.
29. Nguyen SB, Cevic C, Otahbachi M, Kumar A, Jenkins LA, Nugent K. Do comorbid psychiatric disorders contribute to the pathogenesis of tako-tsubo syndrome?: A review of pathogenesis. *Congest Heart Fail* 2009; **15**: 31–34.
30. Delmas C, Lairez O, Mulin E, Delmas T, Boudou N, Dumonteil N, et al. Anxiodepressive disorders and chronic psychological stress are associated with Tako-Tsubo cardiomyopathy: New physiopathological hypothesis. *Circ J* 2013; **77**: 175–180.
31. Sharkey SW, Windenburg DC, Lesser JR, Maron MS, Hauser RG, Lesser JN, et al. Natural history and expansive clinical profile of stress (tako-tsubo) cardiomyopathy. *J Am Coll Cardiol* 2010; **55**: 333–341.
32. Gianni M, Dentali F, Grandi AM, Sumner G, Hiralal R, Lonn E. Apical ballooning syndrome or takotsubo cardiomyopathy: A systematic review. *Eur Heart J* 2006; **27**: 1523–1529.
33. Hasdemir C, Yavuzgil O, Simsek E, Ulucan C, Cinar CS. Stress cardiomyopathy (Tako-Tsubo) following radiofrequency ablation in the right ventricular outflow tract. *Europace* 2008; **10**: 1452–1454.
34. Mohammad M, Patel AK, Koirala A, Asirvatham SJ. Tako-tsubo cardiomyopathy following colonoscopy: Insights on pathogenesis. *Int J Cardiol* 2011; **147**: e46–e49, doi:10.1016/j.ijcard.2009.01.034.
35. Lee VH, Connolly HM, Fulgham JR, Manno EM, Brown RD Jr, Wijdicks EF. Tako-tsubo cardiomyopathy in aneurysmal subarachnoid hemorrhage: An underappreciated ventricular dysfunction. *J Neurosurg* 2006; **105**: 264–270.
36. Lee VH, Oh JK, Mulvagh SL, Wijdicks EF. Mechanisms in neurogenic stress cardiomyopathy after aneurysmal subarachnoid hemorrhage. *Neurocrit Care* 2006; **5**: 243–249.
37. Elesber AA, Prasad A, Lennon RJ, Wright RS, Lerman A, Rihal CS. Four-year recurrence rate and prognosis of the apical ballooning syndrome. *J Am Coll Cardiol* 2007; **50**: 448–452.
38. Summers MR, Prasad A. Takotsubo cardiomyopathy: Definition and clinical profile. *Heart Fail Clin* 2013; **9**: 111–122, vii.
39. Watanabe H, Kodama M, Okura Y, Aizawa Y, Tanabe N, Chinushi M, et al. Impact of earthquakes on Takotsubo cardiomyopathy. *JAMA* 2005; **294**: 305–307.
40. Vieweg WV, Hasnain M, Mezuk B, Levy JR, Lesnefsky EJ, Pandurangi AK. Depression, stress, and heart disease in earthquakes and takotsubo cardiomyopathy. *Am J Med* 2011; **124**: 900–907.
41. Chockalingam A, Mehra A, Dorairajan S, Dellsperger KC. Acute left ventricular dysfunction in the critically ill. *Chest* 2010; **138**: 198–207.
42. Pant S, Deshmukh A, Mehta K, Badheka AO, Tuliani T, Patel NJ, et al. Burden of arrhythmias in patients with Takotsubo Cardiomyopathy (apical ballooning syndrome). *Int J Cardiol* 2013; **170**: 64–68.
43. Dib C, Asirvatham S, Elesber A, Rihal C, Friedman P, Prasad A. Clinical correlates and prognostic significance of electrocardiographic abnormalities in apical ballooning syndrome (Takotsubo/stress-induced cardiomyopathy). *Am Heart J* 2009; **157**: 933–938.
44. Sharkey SW, Lesser JR, Menon M, Parpart M, Maron MS, Maron BJ. Spectrum and significance of electrocardiographic patterns, troponin levels, and thrombolysis in myocardial infarction frame count in patients with stress (tako-tsubo) cardiomyopathy and comparison to those in patients with ST-elevation anterior wall myocardial infarction. *Am J Cardiol* 2008; **101**: 1723–1728.
45. Bybee KA, Motiei A, Syed IS, Kara T, Prasad A, Lennon RJ, et al. Electrocardiography cannot reliably differentiate transient left ventricular apical ballooning syndrome from anterior ST-segment elevation myocardial infarction. *J Electrocardiol* 2007; **40**: 38.e1–e6, doi:10.1016/j.jelectrocard.2006.04.007.
46. Ogura R, Hiasa Y, Takahashi T, Yamaguchi K, Fujiwara K, Ohara Y, et al. Specific findings of the standard 12-lead ECG in patients with ‘Takotsubo’ cardiomyopathy: Comparison with the findings of acute anterior myocardial infarction. *Circ J* 2003; **67**: 687–690.
47. Jim MH, Chan AO, Tsui PT, Lau ST, Siu CW, Chow WH, et al. A new ECG criterion to identify takotsubo cardiomyopathy from anterior myocardial infarction: Role of inferior leads. *Heart Vessels* 2009; **24**: 124–130.
48. Kosuge M, Ebina T, Hibi K, Morita S, Okuda J, Iwahashi N, et al. Simple and accurate electrocardiographic criteria to differentiate takotsubo cardiomyopathy from anterior acute myocardial infarction. *J Am Coll Cardiol* 2010; **55**: 2514–2516.
49. Carrillo A, Fiol M, Garcia-Niebla J, Bayes de Luna A. Electrocardiographic differential diagnosis between Takotsubo syndrome and distal occlusion of LAD is not easy. *J Am Coll Cardiol* 2010; **56**: 1610–1611; author reply 1611.
50. Johnson NP, Chavez JF, Mosley WJ 2nd, Flaherty JD, Fox JM. Performance of electrocardiographic criteria to differentiate Takotsubo cardiomyopathy from acute anterior ST elevation myocardial infarction. *Int J Cardiol* 2013; **164**: 345–348.
51. Kosuge M, Ebina T, Hibi K, Iwahashi N, Tsukahara K, Endo M, et al. Differences in negative T waves between takotsubo cardiomyopathy and reperfused anterior acute myocardial infarction. *Circ J* 2012; **76**: 462–468.
52. Namgung J. Electrocardiographic findings in takotsubo cardiomyopathy: ECG evolution and its difference from the ECG of acute coronary syndrome. *Clin Med Insights Cardiol* 2014; **8**: 29–34, doi:10.4137/CMC.S14086, eCollection 2014.
53. Sharkey SW. Electrocardiogram mimics of acute ST-segment elevation myocardial infarction: Insights from cardiac magnetic resonance imaging in patients with tako-tsubo (stress) cardiomyopathy. *J Electrocardiol* 2008; **41**: 621–625.
54. Mitsuwa W, Kodama M, Ito M, Tanaka K, Yanagawa T, Ikarashi N, et al. Serial electrocardiographic findings in women with Takotsubo cardiomyopathy. *Am J Cardiol* 2007; **100**: 106–109.
55. Chinushi M. Ventricular repolarization gradient and electrocardiogram characteristics of Tako-Tsubo cardiomyopathy. *Heart Rhythm* 2013; **10**: 78–79.
56. Perazzolo Marra M, Zorzi A, Corbetti F, De Lazzari M, Migliore F, Tona F, et al. Apicobasal gradient of left ventricular myocardial edema underlies transient T-wave inversion and QT interval prolongation (Wellens’ ECG pattern) in Tako-Tsubo cardiomyopathy. *Heart Rhythm* 2013; **10**: 70–77.
57. de Zwaan C, Bar FW, Wellens HJ. Characteristic electrocardiographic pattern indicating a critical stenosis high in left anterior descending coronary artery in patients admitted because of impending myocardial infarction. *Am Heart J* 1982; **103**: 730–736.
58. Madhavan M, Borlaug BA, Lerman A, Rihal CS, Prasad A. Stress hormone and circulating biomarker profile of apical ballooning syndrome (Takotsubo cardiomyopathy): Insights into the clinical significance of B-type natriuretic peptide and troponin levels. *Heart* 2009; **95**: 1436–1441.
59. Ahmed KA, Madhavan M, Prasad A. Brain natriuretic peptide in apical ballooning syndrome (Takotsubo/stress cardiomyopathy): Comparison with acute myocardial infarction. *Coron Artery Dis* 2012; **23**: 259–264.
60. Nascimento FO, Yang S, Larrauri-Reyes M, Pineda AM, Cornielle V, Santana O, et al. Usefulness of the troponin-ejection fraction product to differentiate stress cardiomyopathy from ST-segment elevation myocardial infarction. *Am J Cardiol* 2014; **113**: 429–433.
61. Nguyen TH, Neil CJ, Sverdlov AL, Mahadavan G, Chirkov YY, Kucia AM, et al. N-terminal pro-brain natriuretic protein levels in takotsubo cardiomyopathy. *Am J Cardiol* 2011; **108**: 1316–1321.
62. Dewachter P, Tanase C, Levesque E, Nicaise-Roland P, Chollet-Martin S, Mouton-Faivre C, et al. Apical ballooning syndrome following perioperative anaphylaxis is likely related to high doses of epinephrine. *J Anesth* 2011; **25**: 282–285.
63. Khoueiry G, Abi Rafeh N, Azab B, Markman E, Waked A, AbouRjaill G, et al. Reverse Takotsubo cardiomyopathy in the setting of anaphylaxis treated with high-dose intravenous epinephrine. *J Emerg Med* 2013; **44**: 96–99.
64. Manivannan V, Li JT, Prasad A, Campbell RL. Apical ballooning syndrome after administration of intravenous epinephrine during an anaphylactic reaction. *Mayo Clinic Proc* 2009; **84**: 845–846.
65. Paur H, Wright PT, Sikkil MB, Tranter MH, Mansfield C, O’Gara P, et al. High levels of circulating epinephrine trigger apical cardiodepression in a β_2 -adrenergic receptor/Gi-dependent manner: A new model of takotsubo cardiomyopathy. *Circulation* 2012; **126**: 697–706.
66. Wittstein IS, Thiemann DR, Lima JA, Baughman KL, Schulman SP,

- Gerstenblith G, et al. Neurohumoral features of myocardial stunning due to sudden emotional stress. *N Engl J Med* 2005; **352**: 539–548.
67. Yoshioka T, Hashimoto A, Tsuchihashi K, Nagao K, Kyuma M, Ooiwa H, et al. Clinical implications of midventricular obstruction and intravenous propranolol use in transient left ventricular apical ballooning (Tako-tsubo cardiomyopathy). *Am Heart J* 2008; **155**: 526.e1–e7, doi:10.1016/j.ahj.2007.10.042.
 68. Patel SM, Lennon RJ, Prasad A. Regional wall motion abnormality in apical ballooning syndrome (Takotsubo/stress cardiomyopathy): Importance of biplane left ventriculography for differentiating from spontaneously aborted anterior myocardial infarction. *Int J Cardiovasc Imaging* 2012; **28**: 687–694.
 69. Elesber AA, Prasad A, Bybee KA, Valeti U, Motiei A, Lerman A, et al. Transient cardiac apical ballooning syndrome: Prevalence and clinical implications of right ventricular involvement. *J Am Coll Cardiol* 2006; **47**: 1082–1083.
 70. Soriano CJ, Ridocci F, Estornell J, Jimenez J, Martinez V, De Velasco JA. Noninvasive diagnosis of coronary artery disease in patients with heart failure and systolic dysfunction of uncertain etiology, using late gadolinium-enhanced cardiovascular magnetic resonance. *J Am Coll Cardiol* 2005; **45**: 743–748.
 71. McCrohon JA, Moon JC, Prasad SK, McKenna WJ, Lorenz CH, Coats AJ, et al. Differentiation of heart failure related to dilated cardiomyopathy and coronary artery disease using gadolinium-enhanced cardiovascular magnetic resonance. *Circulation* 2003; **108**: 54–59.
 72. De Cobelli F, Pieroni M, Esposito A, Chimenti C, Belloni E, Mellone R, et al. Delayed gadolinium-enhanced cardiac magnetic resonance in patients with chronic myocarditis presenting with heart failure or recurrent arrhythmias. *J Am Coll Cardiol* 2006; **47**: 1649–1654.
 73. Gerbaud E, Montaudon M, Leroux L, Corneloup O, Dos Santos P, Jais C, et al. MRI for the diagnosis of left ventricular apical ballooning syndrome (LVABS). *Eur Radiol* 2008; **18**: 947–954.
 74. Nakamori S, Matsuoka K, Onishi K, Kurita T, Ichikawa Y, Nakajima H, et al. Prevalence and signal characteristics of late gadolinium enhancement on contrast-enhanced magnetic resonance imaging in patients with takotsubo cardiomyopathy. *Circ J* 2012; **76**: 914–921.
 75. Kawai S, Kitabatake A, Tomoike H. Guidelines for diagnosis of takotsubo (apical) cardiomyopathy. *Circ J* 2007; **71**: 990–992.
 76. Naruse Y, Sato A, Kasahara K, Makino K, Sano M, Takeuchi Y, et al. The clinical impact of late gadolinium enhancement in Takotsubo cardiomyopathy: Serial analysis of cardiovascular magnetic resonance images. *J Cardiovasc Magn Reson* 2011; **13**: 67.
 77. Eitel I, von Knobelsdorff-Brenkenhoff F, Bernhardt P, Carbone I, Muellerleile K, Aldrovandi A, et al. Clinical characteristics and cardiovascular magnetic resonance findings in stress (takotsubo) cardiomyopathy. *JAMA: the journal of the American Medical Association* 2011; **306**: 277–286.
 78. Delgado GA, Truesdell AG, Kirchner RM, Zuzek RW, Pomerantsev EV, Gordon PC, et al. An angiographic and intravascular ultrasound study of the left anterior descending coronary artery in takotsubo cardiomyopathy. *Am J Cardiol* 2011; **108**: 888–891.
 79. Hoyt J, Lerman A, Lennon RJ, Rihal CS, Prasad A. Left anterior descending artery length and coronary atherosclerosis in apical ballooning syndrome (Takotsubo/stress induced cardiomyopathy). *Int J Cardiol* 2010; **145**: 112–115.
 80. Parodi G, Citro R, Bellandi B, Provenza G, Marrani M, Bossone E. Revised clinical diagnostic criteria for Tako-tsubo syndrome: The Tako-tsubo Italian Network proposal. *Int J Cardiol* 2014; **172**: 282–283.
 81. Madias JE. Why the current diagnostic criteria of Takotsubo syndrome are outmoded: A proposal for new criteria. *Int J Cardiol* 2014; **174**: 468–470.
 82. Madias JE. Appropriate implementation of echocardiography in Takotsubo syndrome: Earlier and more frequently. *Echocardiography* 2013; **30**: 1123–1125.
 83. Wittstein IS. Stress cardiomyopathy: A syndrome of catecholamine-mediated myocardial stunning? *Cell Mol Neurobiol* 2012; **32**: 847–857.
 84. Redfors B, Shao Y, Omerovic E. Stress-induced cardiomyopathy (Takotsubo): Broken heart and mind? *Vasc Health Risk Manag* 2013; **9**: 149–154.

Supplementary Files

Supplementary File 1

Movie S1. Coronary angiogram (before and after intervention). The left anterior descending artery is initially occluded in its mid segment. Following intervention it is noted to be a large vessel wrapping around the ventricular apex.

Supplementary File 2

Movie S2. Left ventriculogram in the right anterior oblique projection. Note the akinesis in the mid-ventricular and apical segments with preserved function at the base.

Supplementary File 3

Movie S3. Left ventriculogram in the left anterior oblique projection. Note the preserved function at the lateral wall, not typical of takotsubo cardiomyopathy.

Please find supplementary file(s);
<http://dx.doi.org/10.1253/circj.CJ-14-0859>